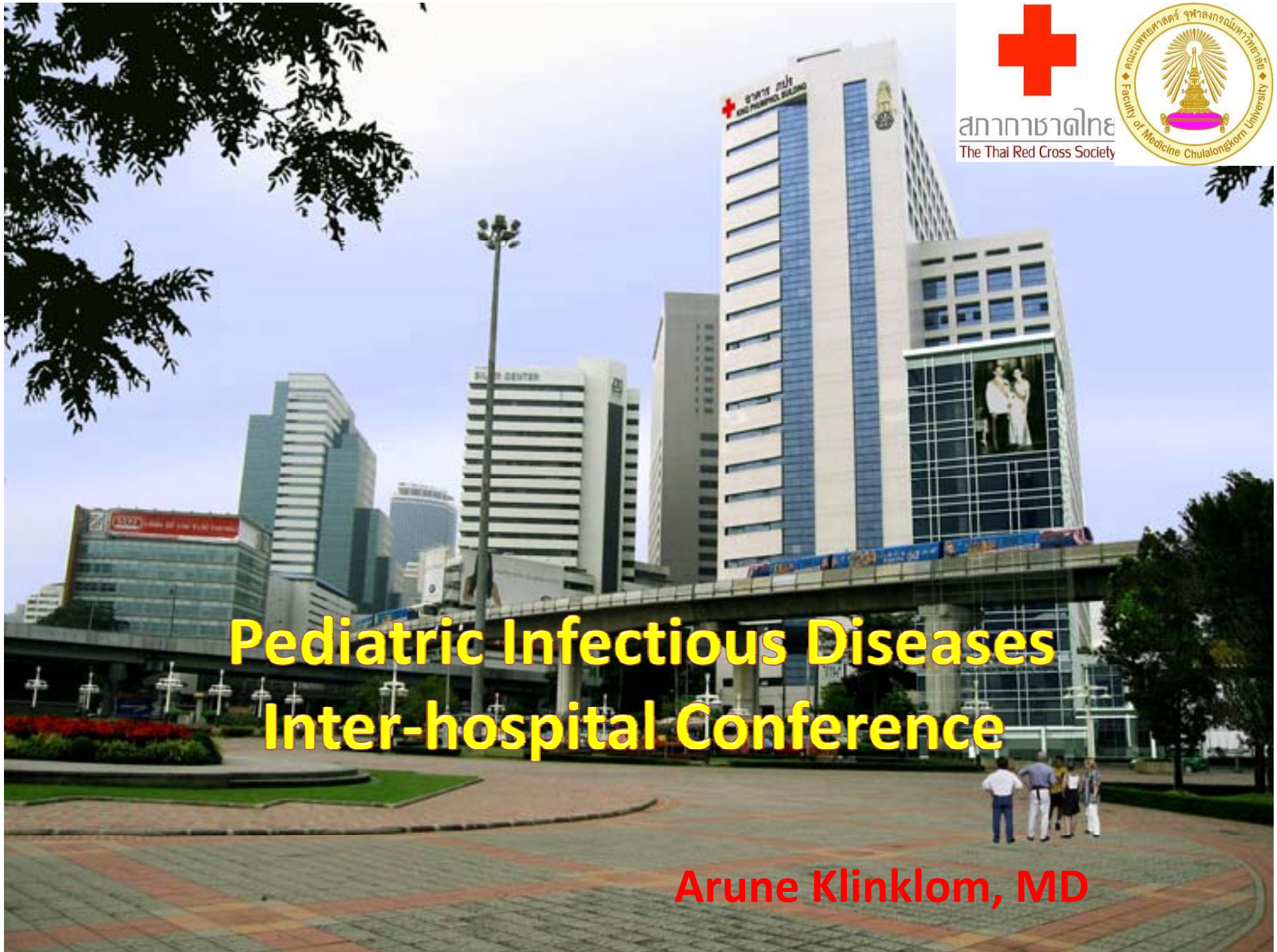



สภาาชาดไทย
The Thai Red Cross Society



Pediatric Infectious Diseases Inter-hospital Conference

Arune Klinklom, MD

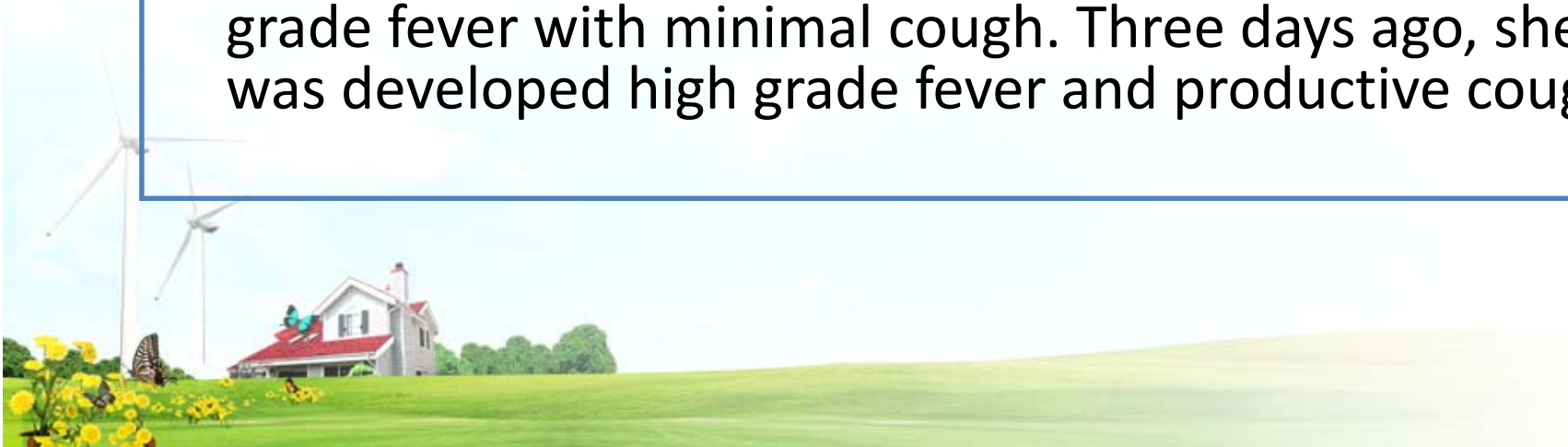
Case Presentation

Patient profile: A 7 years old girl from Klongtoei, BKK.

Underlying Disease: SLE, Hepatitis undefined cause, on Prednisolone (5) 6x1, Mycophenolate mofetil (CellCept) (500) 1x2, Ursodeoxycholic acid (250)1x2

Chief complaint: Fever with cough for 5 days

Present illness: 5 days prior to admission, She had low grade fever with minimal cough. Three days ago, she was developed high grade fever and productive cough.

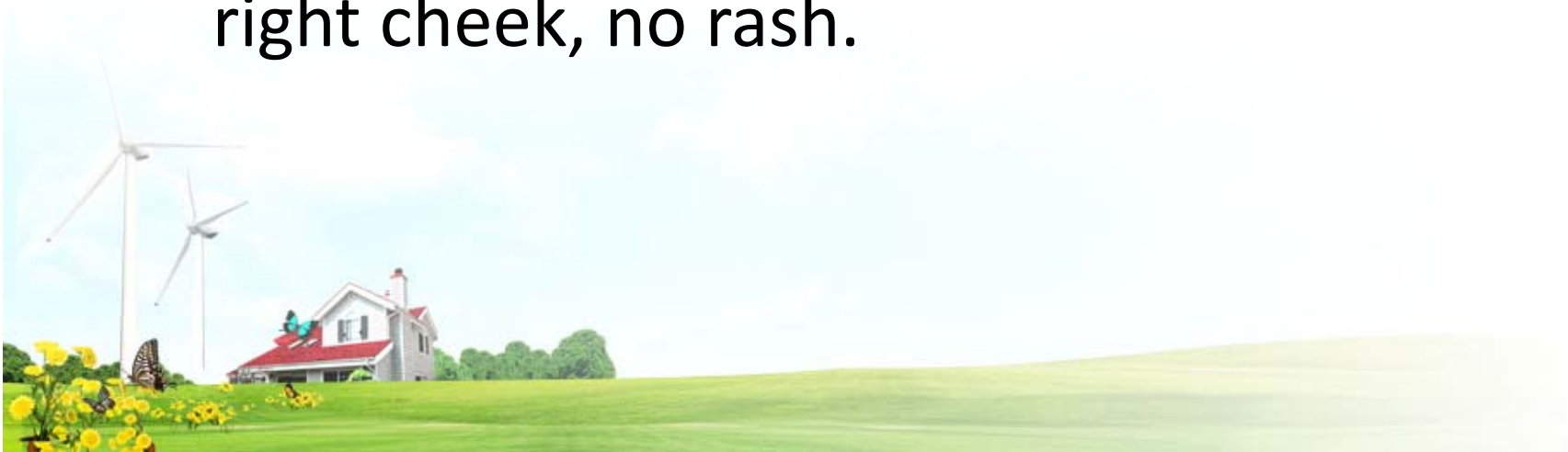

Physical examination (1)

Vital signs :BT 39.5 ° C ,BP 100/60 mmHg ,PR 160/min,full ,RR 32 /min, Wt. 20 Kg(P10), Ht. 109 cm(P10-25)

GA : A Thai girl, cachexia, good consciousness

HEENT: alopecia, mild pale, anicteric sclera, normal P&T, no lymphadenopathy, scar at right cheek, no rash.



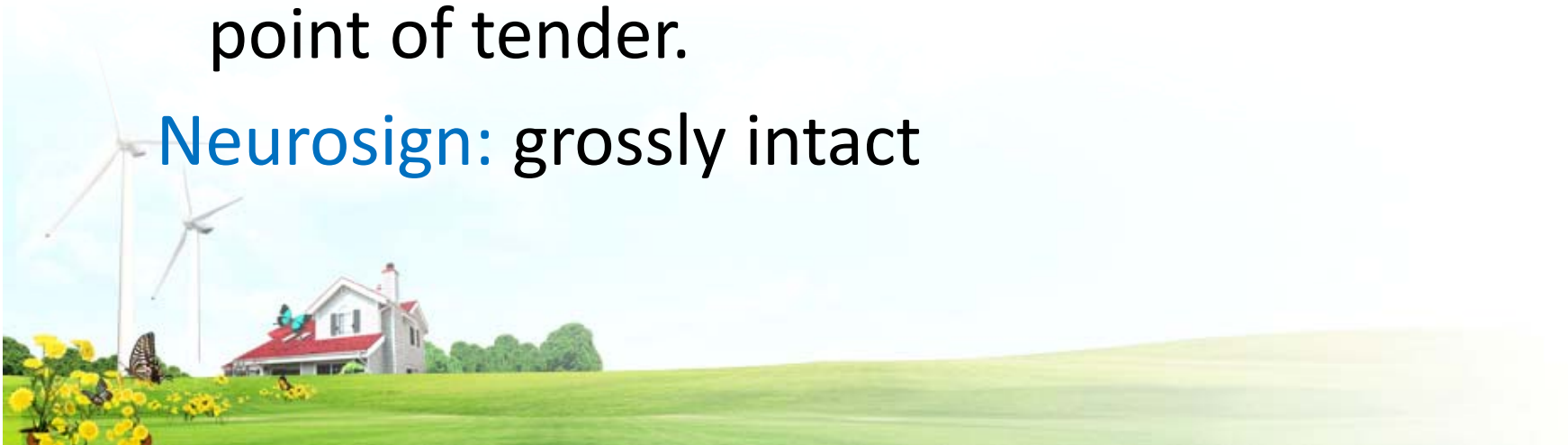
Physical examination (2)

CVS: tachycardia, no murmur

Lung: tachypnea, decreased breath sound Lt.,
no adventitious sound, O₂ at room air 96%

Abdomen: mild distension, not tender, liver 6
cm below RCM, spleen 3 cm below LCM, no
point of tender.

Neurosign: grossly intact



Chest X-ray (Oct 13)

